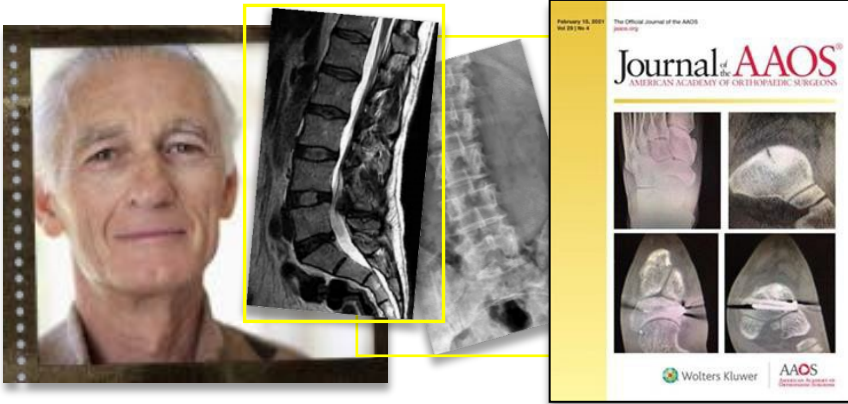

Instructions for Authors

CASES SOLVED!



The AAOS' **Cases Solved!** program is a growing collection of interactive online CME mini-courses written in a narrative format and constructed to mimic real-life patient scenario. Each course presents an evolving patient case scenario based on a *JAAOS* review article, followed by a self-assessment quiz. Patient case scenarios allow learners to experience and manage complex clinical situations, and practice and build important decision-making skills related to diagnosis and treatment. We are now accepting submissions for original Cases Solved! manuscripts.

This author kit includes everything you will need to write your Cases Solved! module. It provides straightforward guidance on what to write for each section of the course, submission guidelines, plus an easy-to-use writing template.

Thank you for your contribution to AAOS Online Learning! We are looking forward to receiving your creative submissions!

Sincerely,

Daniel Blaustein
Learning Designer
American Academy of Orthopaedic Surgeons

LINKS

[Quick Start Instructions](#)

[Writing Template](#)

[Tips for Writing](#)

[Sample Case](#)

CONTACT INFORMATION

Daniel Blaustein
Learning Designer
blaustein@aaos.org

AAOS
AMERICAN ACADEMY OF ORTHOPAEDIC SURGEONS

Author Instructions: Quick Start!

1. Think about an interesting patient case to write about, then visit www.jaaos.org to find a recent topical article on which to base your case.
2. Download the [blank case scenario writing template](#). The template has instructions on how to write-up the case.
3. Write a 10-question multiple-choice quiz based on the article reading and the case.

Estimated length: 1,000-2,000 words including the case write-up and multiple-choice questions.

Submitting Your Case Module

1. To submit your module, images, and other files for editorial review:
 - Click [here](#) to open the submission folder.
 - Click the link to Upload the files from your computer. You may also drag-and-drop the files from your computer.
2. Complete the required publishing form, update your AAOS disclosure, and submit a professional headshot.
 - [Non-Exclusive License form](#). This form grants AAOS the right to publish the lesson material for education purposes while the author retains the copyright.
 - AAOS Disclosure of Potential Conflicts of Interest Click [Disclose Now!](#) to update your information.
3. Submitted activities and proposals will be evaluated by the Editorial Board based on the suitability of the topic, the overall quality of the submission, as well as originality and contribution to the field. Contributors may be asked to revise their submission to address any outstanding editorial comments.
4. Following acceptance, the module will be produced for online publication. The review, production, and publication process will take approximately 4-6 weeks. Contributors will be notified upon the acceptance of the submission as well as the publication of the activity on the AAOS Online Learning Platform.

Case Scenario Writing Template

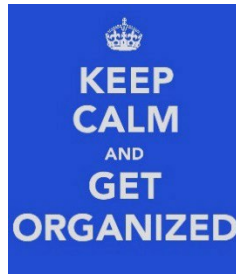This template is your tool to guide the structure of the case. It is not necessary to include every detail, just the relevant information that will help the learner understand the salient teaching points, such as pertinent details needed for diagnosis and treatment decision making. In addition to text you will include all relevant images, such as clinical photos, radiographs, MRI scans, and histology photomicrographs.

Cases should represent contemporary issues and areas of high interest and relevance for orthopaedic surgeons. While submissions on any topic are welcome, we are particularly keen to receive cases related to hip and knee reconstruction, sports medicine, shoulder and elbow pathology, and orthopaedic trauma.

| Section | Sample Content |
|--|---|
| <p>Learning Objectives</p> <p>Learning objectives describe what you intend for the end users to learn.</p> | <ul style="list-style-type: none"> • Describe the general presentation of a Lisfranc injury. • Identify the workup and imaging studies required for diagnosis of a Lisfranc injury. <p>Discuss treatment options for and complications associated with Lisfranc injuries.</p> |
| <p>Case Presentation</p> <p>Describe the essential nature of the complaint, including location, intensity, and associated symptoms.</p> <p>If relevant include details of time and circumstances of onset, relieving and aggravating factors, including responses to other treatment. Include patient demographics and other health history, if relevant.</p> | <p>A 37-year-old man arrives in the emergency department after a motorcycle accident in which he hit a tree traveling at approximately 50 mph. He was helmeted and denies any loss of consciousness. His blood pressure is 130/80 mmHg, his heart rate is 90 beats/minute, and his temperature is 99°F. He complains of significant pain localized to his right foot.</p> |
| <p>Physical Examination</p> <p>Describe physical examination results and findings.</p> | <p>On physical exam, the skin is found to be intact. However, there is significant swelling over the dorsum of the foot as well as plantar ecchymosis..... posterior tibial pulse is palpable, whereas the dorsalis pedis pulse is only appreciated with a Doppler probe....</p> |
| <p>Imaging Studies/Lab Studies/Other Tests</p> <p>Imaging studies, pathological tests, and other investigations (radiographs, MRI, CT, Ultrasound, blood/urine analysis); include a differential diagnosis (short list) and final diagnosis, based on the labs.</p> | <p>AP, lateral, and 30° oblique views of the right foot were ordered and demonstrate.</p> <p>Note: Please submit all images that you intend to use along with your manuscript.</p> |
| <p>Conclusion Management and Outcome</p> <p>Describe as specifically as possible the treatment provided, including the nature of the treatment, and the frequency and duration of care. Describe the resolution of care.</p> | <p>The patient underwent definitive treatment with open reduction and internal fixation to restore anatomic alignment. Screw fixation was used for the first, second, and third TMT joints, whereas the fourth and fifth were pinned with K-wires... Postoperatively, the patient had limited weight bearing for 3 to 5 months and therapy emphasizing passive midfoot range of motion...</p> |

| | |
|---|---|
| <p>10-Question Multiple-Choice Quiz</p> <p>Develop 10 multiple-choice questions based on the article reading and the case. Provide a brief answer feedback for each question. Where you can, provide rationale for incorrect as well as correct answers.</p> <p>Question feedback should include references as necessary.</p> | <p><i>The radiographs show a wide diastasis between the first and second metatarsals. Which of the following ligaments has likely been injured? A) Chopart ligament; B) Deltoid ligament; C) Lisfranc ligament; D) Spring ligament</i></p> <p><i>Preferred response: c</i></p> <p><i>The large diastasis between the first and second metatarsals indicates a TMT joint complex injury. The oblique interosseous ligament or Lisfranc ligament is therefore involved. Answer A is incorrect because the Chopart ligament provides stability to the calcaneocuboid joint. Answer B is incorrect because the deltoid ligament stabilizes the medial side of the ankle. Answer D is incorrect because the spring ligament stabilizes the talonavicular joint</i></p> <p>Reference</p> <p><i>Watson TS, Shurnas PS, Denker J: Treatment of Lisfranc joint injury: Current concepts. J Am Acad Orthop Surg 2010;18:718-728.</i></p> |
| <p>Discussion</p> <p>Summarize the features of the case, and describe the key points covered in the case report</p> | <p><i>This patient's history and presentation are common for an injury to TMT joint complex. The diffuse pain and swelling, specifically over the midfoot and forefoot, are consistent with a high-energy injury mechanism, such as a motorcycle accident, which is often associated with Lisfranc injuries...</i></p> |
| <p>Additional Sample Cases</p> <p><u>Tendinopathies of the Hand and Wrist</u></p> <p><u>Extensor Mechanism Disruption After Total Knee Arthroplasty</u></p> <p><u>Meniscal Root Injury: Case 2</u></p> | |

Tips for Writing Case Scenarios



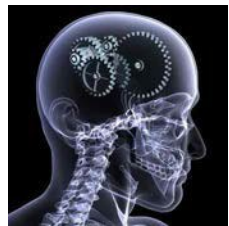
Stay organized

To begin, you must have a clear sense of the value of the case that you are describing and the learning objectives that you want to cover. Therefore, before beginning to write the case scenario itself, be sure to gather all of the materials relevant to the case, such as clinical notes, labs, radiographs, etc.



Write conversationally

Write as if you were talking to a colleague. Avoid stiff or stilted language. This is not a dictated case report.



Challenge learners with higher-level and active learning

Higher-level learning engages the learner with active forms of thinking such as problem solving, decision-making, critical thinking, reflective thinking, and creative thinking. Higher-level learning and active learning require constructive feedback for learners to know whether they are "doing it" correctly. The answer feedback should be used to reinforce the key concepts as they relate to the learning objectives.



Give constructive feedback to learners

Use feedback to dispel common misconceptions not grounded in clinical evidence. Where you can, try to provide the rationale for why the correct answer is appropriate, and explain why the incorrect options are not the best responses. If you have a favorite referential article, or further reading, feel free to mention it here.



Stick to the facts

A case study should be a fairly modest description of what actually happened. Speculation about underlying mechanisms of the disease process or treatment should be restrained. The thing of greatest value that you can provide to your colleagues is an honest record of clinical events.