

# ARTICULAR CARTILAGE RESTORATION: A REVIEW OF CURRENTLY AVAILABLE METHODS

AMERICAN ACADEMY OF ORTHOPAEDIC SURGEONS  
77TH ANNUAL MEETING  
MARCH 9 - 13, 2010  
NEW ORLEANS, LOUISIANA

COMMITTEE ON BIOLOGICAL IMPLANTS

MICHAEL E. TRICE, M.D.  
WILLIAM D. BUGBEE, M.D.  
A. SETH GREENWALD, D.PHIL.(OXON)  
CHRISTINE S. HEIM, B.Sc.

# INTRODUCTION

Articular cartilage repair and restoration is an emerging clinical treatment option for patients with injury or disease of articular cartilage. An increasing body of clinical and scientific experience, as well as published literature, supports the rationale, technical aspects and clinical outcome of various methodologies in current clinical use. As a result, cartilage repair treatment is moving out of the realm of the subspecialist and becoming more widespread in the orthopaedic community. In addition, many “next generation” technologies and devices are under investigation and may soon be available for clinical application in the US. Nonetheless, there remains significant controversy and debate regarding the most appropriate use of each of the cartilage repair modalities available to orthopaedic surgeons. At the same time, patients and the general public, often fueled by popular media, are actively seeking out so-called biologic treatment options for joint injury and disease.

This exhibit reviews the four most commonly employed cartilage repair techniques: Microfracture (MFX), Autologous Chondrocyte Implantation (ACI), Osteochondral Autograft Transfer (OAT) and Osteochondral Allografting (OCA). Each of these techniques has a basic science supported rationale, established patient selection criteria, optimum surgical technique and supportive clinical outcome data. When carefully considered, these techniques provide the surgeon with a fundamentally sound basis for choosing the most appropriate intervention for a particular patient.

## MICROFRACTURE

### Rationale and Basic Science

Microfracture (MFX) is considered a first-line treatment for articular cartilage injury by many orthopaedists. The procedure is performed by removing all damaged articular cartilage then making a series of small holes in the subchondral plate with awls or picks. This leads to bleeding, clot formation, as well as the introduction of marrow derived stem cells to the site. These stem cells are thought to mediate a fibrocartilaginous repair of the defect. Fibrocartilage is best described as a repair tissue that differs from normal articular cartilage in that it is less durable, less organized, and has a higher proportion of Type I collagen than normal articular cartilage.

### Indications

The indications for MFX are somewhat controversial. While some orthopaedists consider MFX the first-line treatment for all articular cartilage defects, others see it as a treatment that is only useful in select circumstances. It is widely accepted that MFX should be considered as first-line treatment for near full-thickness or full-thickness articular cartilage injuries (Outerbridge grade III or IV) that measure 2 cm<sup>2</sup> or less. Although 2 cm<sup>2</sup> is the maximal sized lesion that many surgeons will MFX, these indications are by no means universally accepted. Some believe 1 cm<sup>2</sup> should be the maximum while others believe the procedure can be successful in lesions well over 2 cm<sup>2</sup>.

### Surgical Technique

- Detailed operative consent obtained for MFX procedure
- A complete diagnostic arthroscopy is performed
- The lesion is:
  - Identified and measured
  - Debrided:
    1. To obtain vertical borders
    2. To remove calcified cartilage layer
  - Microfractured - multiple holes are made 3 - 4 mm apart with awls or picks
  - Rehabilitation generally includes continuous passive motion therapy and limited weight bearing for 6 - 8 weeks

### Outcomes

- Steadman et al<sup>14</sup> noted a 95% improved function in their MFX population at 11.3 years. More than 20% of patients, however, found their pain equal to or greater than it was prior to surgery.
- Kreuz et al<sup>9</sup> found that the results of MFX deteriorate after 18 months. They found better outcomes in patients under 40 years of age. Their best results were in femoral condylar lesions and they noted less satisfactory results in patellar, trochlear, and tibial lesions.
- Gobbi et al<sup>6</sup> followed 53 athletes for 72 months and found 70% improvement in pain and swelling but 80% of their subjects noted a decline in sports activity at final follow up.

### Future Advances

There has been some interest in development of variations on the theme of MFX that might yield better outcomes in the future. Microfracture has been supplemented with barrier implantation to minimize egress of the marrow elements with the hopes of making a better repair. Other stem cell implantations are being considered as an adjunct or alternative to MFX.

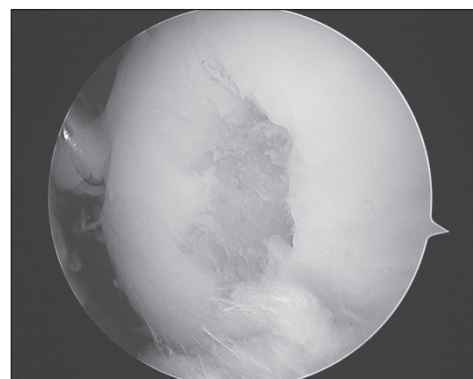


Figure 1: < 1 cm<sup>2</sup> articular cartilage defect

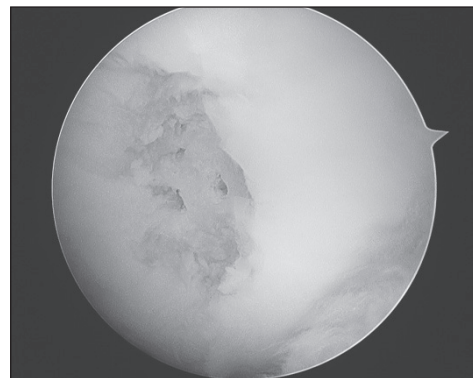


Figure 2: < 1 cm<sup>2</sup> defect after MFX

# AUTOLOGOUS CHONDROCYTE IMPLANTATION

## Rationale and Basic Science

Autologous chondrocyte implantation (ACI), was first performed by Peterson in 1987. Brittberg et al<sup>3</sup> published their initial results in the New England Journal of Medicine in 1994. Autologous chondrocytes are harvested then expanded in tissue culture medium. They are reimplanted under a periosteal patch and the reimplanted cells produce new cartilage tissue repair.

## Indications

It is widely held that ACI is indicated for near full- or full-thickness lesions of articular cartilage (Outerbridge grade III or IV) of 2 cm<sup>2</sup> or greater. However, some controversies exist. Some believe ACI should be reserved for patients who have failed another primary intervention (e.g. MFX), while others believe results are better when ACI is employed as a primary technique. There is also a trend towards treating smaller lesions (as small as 1 cm<sup>2</sup>) with primary ACI.

## Surgical Technique

- ACI requires two procedures
- Procedure 1 - Diagnostic arthroscopy
  - Articular cartilage is harvested from a non-weight bearing area of the knee
  - Prior to Procedure 2, chondrocytes are expanded in cell culture. At biopsy ~300,000 cells are harvested and after expansion there are up to 12 million cells.
- Procedure 2 - Implantation procedure
  - Expanded cells are retrieved prior to procedure
  - At arthrotomy the defect is prepared. Preparation includes debridement to remove all residual damaged cartilage without injuring subchondral bone. Vertical borders of healthy cartilage surrounding the defect are obtained.
  - The defect is measured and a periosteal patch is prepared
  - The patch is sutured over the defect with 6-0 absorbable suture
  - Any concomitant procedures (i.e. osteotomy, ligament reconstruction, meniscal allograft transplantation) are completed
  - Expanded cells are removed from vials and injected under the periosteal patch
  - The patch is sealed with additional suture and fibrin glue
  - The arthrotomy is closed and rehabilitation is begun

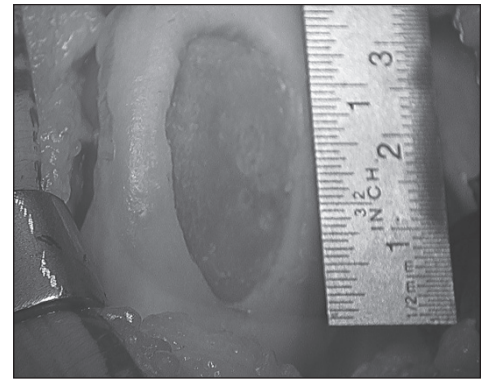


Figure 3: > 2 cm<sup>2</sup> articular cartilage defect

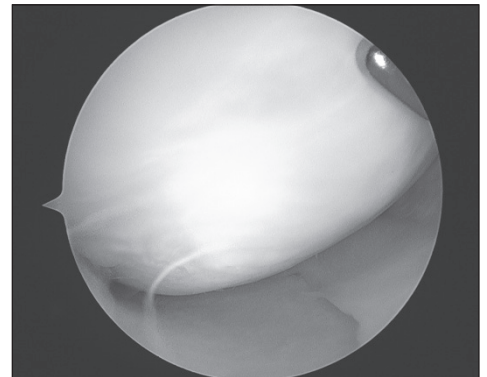


Figure 4: 2 years after ACI second look arthroscopy of a > 2 cm<sup>2</sup> lesion

## Outcomes

- Peterson et al<sup>13</sup> studied 61 ACI patients at a mean of 7.4 years and 82% of these patients had good or excellent results. Cartilage stiffness was near normal (90%) in 8 of 11 patients who underwent second-look arthroscopy.
- Mithöfer et al<sup>12</sup> found 96% adolescent athletes had good or excellent results at a mean of 47 months. Also 96% of these athletes returned to high-impact sports.
- Zaslav et al<sup>15</sup> published a randomized prospective trial in which they studied 126 ACI patients who had failed prior procedures. In spite of prior surgery, there was a 76% success rate at 48 months follow-up.

## Future Advances

There are new developments in ACI that have become popular in Europe. One new modification employs patches from alternative sources (e.g. porcine collagen bilayer membranes) instead of periosteum for ACI. Also, matrices impregnated with expanded chondrocytes are now placed in defects as an alternative to traditional ACI.

# OSTEOCHONDRAL AUTOGRAFT TRANSFER

## Rationale and Basic Science

The concept of osteochondral autograft transfer (OAT) for cartilage repair was introduced by Bobić<sup>2</sup> (single plugs) and Hangody et al<sup>8</sup> (multiple plugs or “Mosaicplasty”) in the late 1990’s. Osteochondral autografting involves transplanting structurally intact osteochondral tissue from a remote, relatively non-load bearing site, to a load bearing defect site. Intact hyaline cartilage, which closely replicates the lost tissue, is potentially more durable and biomechanically normal than a fibrocartilage repair. Osseointegration of the autograft proceeds similarly to any bone autograft and the hyaline cartilage portion survives and maintains normal tissue homeostasis with intact hyaline cartilage structure. The issue of morbidity of the donor graft site is not completely resolved, but does limit the use of this procedure to smaller focal lesions. The introduction of specially designed surgical instruments and the relative low cost of the procedure have generated interest in this technique for cartilage repair of smaller focal lesions.

## Indications

Osteochondral autografting is generally used for smaller focal lesions of the femoral condyle no greater than 1.5 to 2 cm. The size (diameter) and number of plugs required to fill a defect is also an important consideration.

- Traumatic chondral lesions
- Failure of surface treatments with lesion size less than 2 cm
- Small osteochondral lesions - presence of bone cyst or intralesional osteophyte
- Osteochondritis dissecans - use as combination bone graft and fixation device of salvageable fragments

## Surgical Technique

- Available instruments can create cylindrical grafts between 4 and 12 mm diameter
- Osteochondral autografting is performed arthroscopically or utilizing a variable mini arthrotomy (often for graft harvest)
- Accessory portals are often necessary to access lesions perpendicular to the joint surface
- Evaluate lesion to confirm appropriateness for technique and determine size and number of grafts needed
- Confirm adequacy of donor site cartilage (medial or lateral trochlea or notch)
- Harvest donor plugs first to ensure adequacy of grafts before creating recipient site
- Maintaining instrument perpendicular to the joint surface, harvest graft at least 8 mm long
- Prepare recipient site (lesion) with either hand corer or power drill, maintain perpendicularity and ensure socket is at least as deep as the graft length. Measure for accuracy.
- Trim donor plug or deepen socket to match graft to recipient site
- Using graft inserter, gently place graft. Care should be taken not to forcefully impact the graft, which may lead to graft fracture or chondrocyte death.
- Graft should be flush and match contour of surrounding articular surface

## Outcomes

- Hangody et al<sup>8</sup> reported 92% good or excellent results for femoral condyle grafting at 1 - 10-year follow up in 597 knees, utilizing either single or multiple plugs
- Marcacci et al<sup>10</sup> reported 77% good or excellent results at average 7 years for lesions of the femoral condyle
- Miniaci et al<sup>11</sup> reported 100% healing of unstable osteochondritis lesions treated with multiple 4.5 mm osteochondral grafts

## Future Advances

Donor site morbidity remains an issue and new methods to “backfill” are being evaluated. Synthetic osteochondral cores are being developed that may facilitate repair without the use of osteochondral tissue. The procedure is technique sensitive and improvements in instrumentation should enhance outcomes.

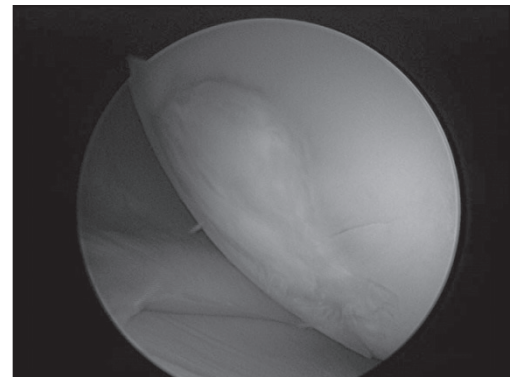


Figure 5: Fibrocartilage defect weight bearing surface medial femoral condyle

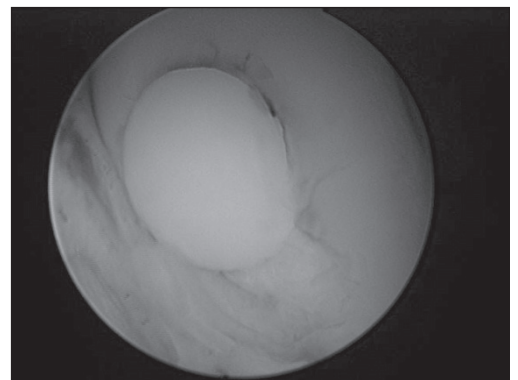


Figure 6: Osteochondral autograft after seating into prepared socket

# OSTEOCHONDRAL ALLOGRAFTING

## Rationale and Basic Science

Fresh osteochondral allografting (OCA) was first described by Eric Lexer in Germany in 1908 and emerged in the 1970's as a treatment option for large post traumatic injuries, osteonecrosis and certain juxta-articular tumors. The 1990's saw the advent of OCA for treatment of focal osteochondral defects such as osteochondritis dissecans.

The scientific basis of osteochondral allografting is the transplantation of mature hyaline cartilage containing living chondrocytes that survive transplantation and support the hyaline cartilage matrix indefinitely, in theory maintaining tissue homeostasis.<sup>7</sup> Retrievals have shown viable chondrocytes as long as 29 years after transplantation. The osseous portion of the graft serves as an osteoconductive scaffold for graft incorporation and often to restore missing bone. The osteochondral graft is considered relatively immunoprivileged, being both non-vascularized and having the chondrocytes protected from host immune surveillance within the hyaline matrix. Technology for prolonged storage of osteochondral grafts has led to commercialization of graft processing and distribution. Allograft cost and availability remain key hurdles to clinical application.

## Indications

Osteochondral allografts are particularly suited for osteochondral lesions such as osteochondritis dissecans, focal osteonecrosis or periarticular trauma where bone deformity or deficiency occurs in association with chondral disease.

- Chondral and osteochondral lesions greater than 2 cm<sup>2</sup>
- Revision or salvage of other cartilage surgery
- Osteochondritis dissecans type III or IV
- Osteonecrosis
- Post traumatic reconstruction

## Surgical Technique

- Available instruments can create grafts between 10 and 35 mm diameter
- Osteochondral allografting is performed through a mini or standard arthrotomy
- The defect is exposed and sized and a guide pin placed through the center of the lesion, perpendicular to the joint surface
- The lesion is reamed to a modest depth removing diseased cartilage and a small (3 - 6 mm) amount of bone
- Depth measurements are taken from the prepared recipient site
- The allograft plug is removed from the donor tissue utilizing a coring reamer
- Recipient depth measurements are marked on the plug and excess bone removed, creating an osteochondral graft matching the size and depth of the prepared recipient site
- The graft is lavaged to remove blood and debris and bony edges trimmed to facilitate insertion
- The graft is gently inserted with a tamp or with joint compression during range of motion
- Loose grafts are fixed with absorbable pins or screws

## Outcomes

- Aubin et al<sup>1</sup> reported 85% 10 year survivorship of 60 allografts performed for post traumatic defects of the femur
- Emmerson et al<sup>5</sup> reported 80% good and excellent results at mean of 6 years in the treatment of osteochondritis dissecans (average graft surface 7.4 cm)
- Chu et al<sup>4</sup> reported 84% good and excellent results at 6.2-year follow-up using allografts for a variety of knee conditions

## Future Advances

Advances in tissue banking and improved graft storage technology should improve availability and safety. Augmentation of allograft incorporation and viability with cell or molecular based adjuncts is possible. Use of allografts as a scaffold or cell source in tissue engineered products is under investigation.

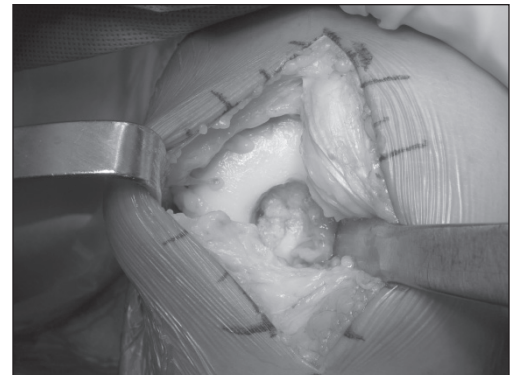


Figure 7: Large type IV osteochondritis dissecans of the medial femoral condyle



Figure 8: Osteochondral allograft has been placed into the prepared defect



## SUMMARY

- Cartilage repair and restoration is a relatively new and increasingly important part of orthopaedic care. Knowledge and understanding of the available surgical techniques is critical to the appropriate use of these interventions.
- The four most common techniques: microfracture, autologous chondrocyte implantation, autologous osteochondral transfer and osteochondral allografting are presented. These are not the only methods with which to treat individuals with damaged or diseased articular cartilage. Other techniques have been reported and many new technologies are in scientific or product development or clinical trials.
- Management of any abnormalities of so-called “background factors” such as limb or patellofemoral malalignment, joint instability and meniscal deficiency is an important component of any cartilage treatment program.
- Surgeons wishing to advance their understanding and skill should consider attending a course focusing on cartilage repair.

## REFERENCES

1. Aubin PP, Cheah HK, Davis AM, Gross AE. Long term follow-up of fresh femoral osteochondral allografts for post traumatic defects of the knee. *Clin Orthop Relat Res.* 2001 391S:318-27.
2. Bobić V. Arthroscopic osteochondral autograft transplantation in anterior cruciate ligament reconstruction: a preliminary clinical study. *Knee Surg Sports Traumatol Arthrosc.* 1996 3(4):262-4.
3. Brittberg M, Lindahl A, Nilsson A, Ohlsson C, Isaksson O, Peterson L. Treatment of deep cartilage defects in the knee with autologous chondrocyte transplantation. *N Engl J Med.* 1994 Oct 6;331(14):889-95.
4. Chu CR, Convery FR, Akeson WH, Meyers M, Amiel D. Articular cartilage transplantation. Clinical results in the knee. *Clin Orthop Relat Res.* 1999 Mar;(360):159-68.
5. Emmerson BC, Görtz S, Jamali AA, Chung C, Amiel D, Bugbee WD. Fresh osteochondral allografting in the treatment of osteochondritis dissecans of the femoral condyle. *Am J Sports Med.* 2007 35(6):907-14.
6. Gobbi A, Nunag P, Malinowski K. Treatment of full thickness chondral lesions of the knee with microfracture in a group of athletes. *Knee Surg Sports Traumatol Arthrosc.* 2005 Apr;13(3):213-21. Epub 2004 May 14.
7. Görtz S, Bugbee WD. Allografts in articular cartilage repair. *J Bone Joint Surg Am.* 2006 Jun;88(6):1374-84.
8. Hangody L, Fules P. Autologous osteochondral mosaicplasty for the treatment of full-thickness defects of weight-bearing joints: ten years of experimental and clinical experience. *J Bone Joint Surg Am.* 2003 85 (Suppl 2):25-32.
9. Kreuz PC, Steinwachs MR, Erggelet C, Krause SJ, Konrad G, Uhl M, Südkamp N. Results after microfracture of full-thickness chondral defects in different compartments in the knee. *Osteoarthritis Cartilage.* 2006 Nov;14(11):1119-25. Epub 2006 Jul 11.
10. Maccacci M, Kon E, Delcogliano M, Filardo G, Busacca M, Zaffagnini S. Arthroscopic autologous osteochondral grafting for cartilage defects of the knee: prospective study results at a minimum 7-year follow-up. *Am J Sports Med.* 2007 35(12):2014-21.
11. Miniaci A, Tytherleigh-Strong G. Fixation of unstable osteochondritis dissecans lesions of the knee using arthroscopic autogenous osteochondral grafting (Mosaicplasty). *Arthroscopy.* 2007 23(8):845-51.
12. Mithöfer K, Peterson L, Mandelbaum BR, Minas T. Articular cartilage repair in soccer players with autologous chondrocyte transplantation: functional outcome and return to competition. *Am J Sports Med.* 2005 Nov;33(11):1639-46. Epub 2005 Aug 10.
13. Peterson L, Brittberg M, Kiviranta I, Akerlund EL, Lindahl A. Autologous chondrocyte transplantation. Biomechanics and long-term durability. *Am J Sports Med.* 2002 Jan-Feb;30(1):2-12.
14. Steadman JR, Briggs KK, Rodrigo JJ, Kocher MS, Gill TJ, Rodkey WG. Outcomes of microfracture for traumatic chondral defects of the knee: average 11-year follow-up. *Arthroscopy.* 2003 May-Jun;19(5):477-84.
15. Zaslav K, Cole B, Brewster R, DeBerardino T, Farr J, Fowler P, Nissen C; STAR Study Principal Investigators. A prospective study of autologous chondrocyte implantation in patients with failed prior treatment for articular cartilage defect of the knee: results of the Study of the Treatment of Articular Repair (STAR) clinical trial. *Am J Sports Med.* 2009 Jan;37(1):42-55. Epub 2008 Oct 16.